CASE REPORT

Presentation of Gall Stone Ileus as Gut Obstruction

Munir Ahmad Wani M.S.,[1] Mubarak Ahmad Shan M.S.,[2] Syed Muzamil Andrabi M.S.,[3] Ajaz Ahmad Malik M.S.[4]

[1] Additional Professor,[2,] [3] Senior Resident, [4]Professor
Department of General and Minimal Invasive Surgery SKIMS.

ABSTRACT

Gallstone ileus is an uncommon and often life-threatening complication of cholelithiasis. In this case report, we discuss a difficult diagnostic case of gallstone ileus presenting as small gut obstruction with ischaemia. A 56-year-old female presented with abdominal pain and vomiting. A CT scan was performed and showed an evolving bowel obstruction with features of gut ischemia with pneumobilia although no frank hyper density suggestive of a gallstone was noted. The patient underwent emergency surgery and a 60 mm obstructing calculus was removed from the patient's jejunum,with a formal tube cholecystostomy. JMS 2018: 21 (2):117-119

INTRODUCTION

Gallstone ileus is a rare complication of choleliathiasis. It has a propensity to affect females and accounts for less than 0.5% of cases of mechanical small bowel obstruction. [1-2] It occurs when gallstone enters the small bowel through a biliary enteric fistula, with more than half of these being cholecystoduodenal fistulas. This fistula is created as the gallstone exerts pressure against the biliary wall, leading to necrosis of GB wall.[3] A bowel obstructions then occurs if the newly entered gallstone is of sufficient size, usually greater than 2 cm.[4] The ileum is the narrowest part of the bowel and is thus the area affected in the majority of cases.[2,5]

Clinically, gallstone ileus presents as an episodic bowel obstruction with diffuse abdominal pain and vomiting. Interval improvement in symptoms may occur as the stone becomes dislodged, with symptoms recurring as the stone becomes repeatedly obstructed.[5] Contrast Tomography is most often used in the investigation of gallstone ileus,[6–8] as only a minority of gallstones have sufficient calcium content to be visible on abdominal X-ray.[9,10] Management of gallstone ileus is predominantly surgical, usually involving an enterolithotomy with or without additional procedures.

A 56-year-old female presented to the emergency department of SKIMS, Srinagar as a referral case with chief complaint of abdominal pain, vomiting and with conservative management for three days. On examination, she was sick with pulse rate of 110 with blood pressure of 100/60 with abdomen distended, mildly tender in all quadrants, more tender in her right lower quadrant. Her blood results showed an elevated white cell count of $12.9 \times 10^9 l^{-1}$ and a neutrophil count of 86%. Furthermore, her lactate level was 4.5-mmol/l. An abdominal ultrasound showed gaseous distension of gut loops with pnemobilia and no calculi within the gallbladder. Gallbladder wall thickness was not assessed. A contrast CT was done. The CT showed abnormal dilatation of the proximal small bowel with a possible transition point in the left iliac fossa with findings suggestive of gut ischemia. Pneumobilia was also noted due to prominence of the hepato- biliary tree. No evidence of a ductal calculus was observed.

After further review and discussion with the treating team, it was revealed that there was no history of any endoscopic retrograde cholangio-pancreatography or cholecystectomy history in past.

The patient underwent a laparotomy and a gallstone was found obstructing the distal jejunum. A 60 mm gallstone was removed by vertical enterotomy, and cholecystostomy was done. The patient had an uneventful recovery in

Correspondence
Dr. Munir Ahmad Wani.
Additional Professor
Department of General and MI Surgery SKIMS, Srinagar
Email:munirwani1971@gmail.com

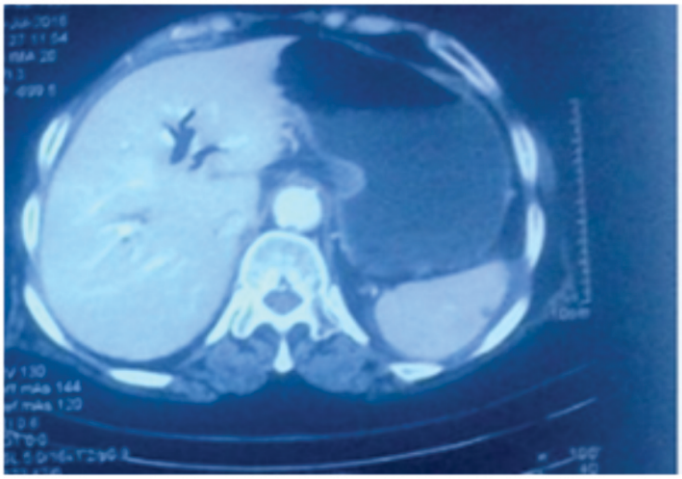

Fig.1: Pnemobilia with air in IHBR

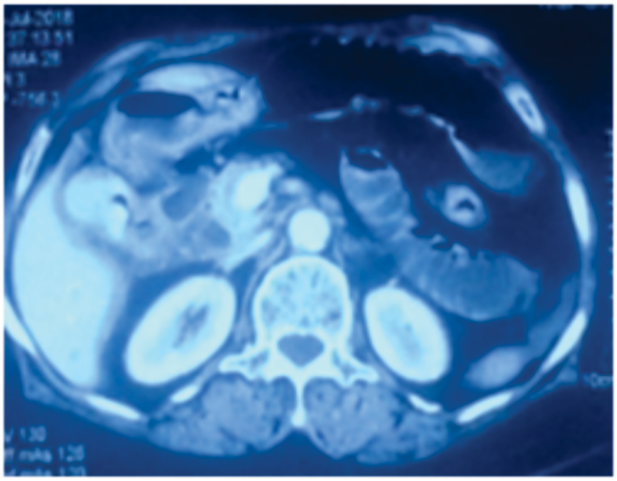

Fig. 2: Thick walled GB and Duodenum.

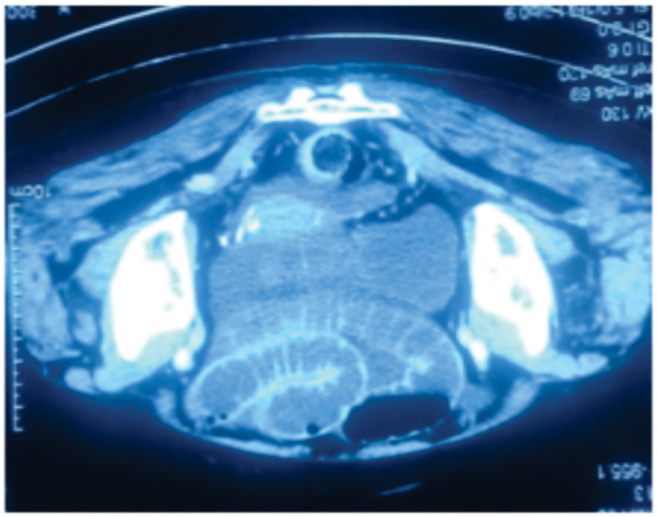

Fig. 3: Dilated small gut loops.

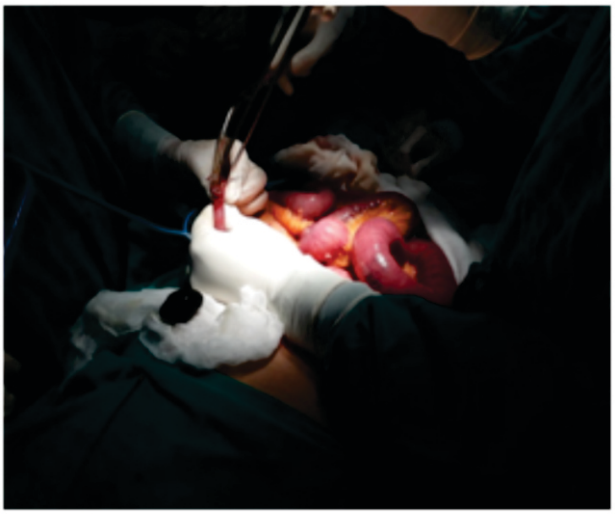

Fig. 4: Obstructing Gallstone delivered at operation.

hospital and was discharged a six days later to a regional hospital for rehabilitation.

DISCUSSION

This case represents what was initially a missed diagnosis of gallstone ileus due to a non-calcified gallstone. The pneumobilia was at first reported as being due to a previous sphincterotomy. The diagnosis of gallstone ileus was made later only after exploration.

The CT findings of gallstone ileus include thickening of the gallbladder wall, pneumobilia and bowel obstruction with obstructing gallstones.[6–8] However, gallstones may be missed on CT as they are not always hyperdense.[9,10] In one study, low density stones accounted for around 3% of gallstones.[9] In this case, gas was appreciated within the thick walled gall bladder and in intrahepatic biliaryradicals. This is a well-documented sign of gallstones in the literature.[11] In addition to this duodenum was thick walled and no cholecystoduodenal fistula could be seen on CT.

Management of gallstone ileus involves removal of the obstructing stone leading to resolution of the bowel obstruction. This is achieved through either a laparoscopic or open enterolithotomy. It is not uncommon for a bowel resection to be required if surgical complications such as perforation or difficult stone retrieval occur.[5] A definitive procedure to treat the cause of the ileus, such as a cholecystectomy or fistula closure is also often required, to reduce other complications such as recurrence or cholecystitis.[5] This procedure can often be performed at the same time as an enterolithotomy in low-risk patients.[2,12,13] Higher risk patients, such as in the case discussed, may undergo enterolithotomy without an additional procedure as fistulas may close or reduce in size without subsequent intervention.[14,15]

Gallstone ileus remains an important diagnosis as it results in significant morbidity and mortality. The mortality rate remains high at around 5–7%.[1,14,16] Furthermore, the mortality rate is 5 to 10 times higher than other mechanical causes of small bowel obstruction.1Recurrent gallstone ileus occurs in a significant minority of patients treated with enterolithotomy alone, and more than half of these occur in the first 6 months following surgery.[14]

This case emphasizes the importance in considering gallstone ileus as a cause for a mechanical bowel obstruction. It demonstrates a difficult diagnostic case of gallstone ileus with no evidence of calcification or increased density on CT that would be suggestive of an obstructing gallstone. The radiological diagnosis of gallstone ileus certainly changed management immediately and may have saved this frail patient. Difficulty in diagnosis was further compounded by conflicting physical examination findings with a seemingly inconclusive abdominal ultrasound study. There is a need for careful consideration of clinical history in conjunction with other radiological signs such as pneumobilia or bowel obstructionto establish a diagnosis of gallstone ileus.

REFERENCES

1. Halabi WJ , Kang CY , Ketana N , Lafaro KJ , Nguyen VQ , Stamos MJ , et al . Surgery for gallstone ileus: a nationwide comparison of trends and outcomes. *Ann Surg*2014;**259**: 329 – 35. Crossref, Medline, ISI, Google Scholar
2. AyantundeAA, Agrawal A. Gallstone ileus: diagnosis and management. *World J Surg*2007 ;**31** : 1294 – 9 . Crossref, ISI, Google Scholar
3. Basili G , Lorenzetti L , Celona G , Biondi G , Preziuso E , Angrisano C , et al . Gallstone ileus in patient with Crohn's disease: report of a clinical observation. *SurgEndosc*2006;**20**: 703 – 4 .Crossref, Medline, ISI, Google Scholar
4. DeitzDM,StandageBA, Pinson CW , McConnell DB , Krippaehne WW. Improving the outcome in gallstone ileus. *Am J Surg*1986;**151**: 572 – 6.Crossref, Medline, ISI, Google Scholar
5. ClavienPA ,Richon J , Burgan S , Rohner A . Gallstone ileus. *Br J Surg*1990;**77**: 737 – 42. Crossref, Medline, ISI, Google Scholar
6. Seal EC,CreaghMF, Finch PJ. Gallstone ileus: a new role for abdominal computed tomography. *Postgrad Med J*1995;**71**: 313 – 5. Crossref, Medline, ISI, Google Scholar
7. Lassandro F , Gagliardi N , Scuderi M , Pinto A , Gatta G , Mazzeo R . Gallstone ileus analysis of radiological findings in 27 patients. *Eur J Radiol*2004;**50**: 23 – 9. Crossref, Medline, ISI, Google Scholar
8. Lassandro F , Romano S , Ragozzino A , Rossi G , Valente T , Ferrara I , et al . Role of helical CT in diagnosis of gallstone ileus and related conditions. *AJR Am J Roentgenol*2005 ;**185** : 1159 – 65 . Crossref, Medline, ISI, Google Scholar
9. Barakos JA , Ralls PW , Lapin SA , Johnson MB , Radin DR , Colletti PM , et al . Cholelithiasis: evaluation with CT. *Radiology*1987;**162**: 415 – 8. Crossref, Medline, ISI, Google Scholar
10. Benarroch-GampelJ , Boyd CA , Sheffield KM , Townsend CM , Riall TS . Overuse of CT in patients with complicated gallstone disease. *J Am CollSurg*2011;**213**: 524 – 30. Crossref, Medline, ISI, Google Scholar
11. DelabrousseE ,Bartholomot B , Narboux Y , Barrali E , Chirouze C , Kastler B. Gas-containing gallstones: value of the "Mercedes-Benz" sign at CT examination . *J Radiol*2000;**81**: 1639 – 41. Medline, Google Scholar
12. Rodríguez-SanjuánJC,CasadoF,FernándezMJ, Morales DJ, Naranjo A. Cholecystectomy and fistula closure versus enterolithotomy alone in gallstone ileus. *Br J Surg*1997;**84**: 634 – 7. Crossref, Medline, ISI, Google Scholar
13. Lobo DN, Jobling JC, Balfour TW . Gallstone ileus: diagnostic pitfalls and therapeutic successes. *J ClinGastroenterol*2000;**30** : 72 – 6 . Crossref, Medline, ISI, Google Scholar
14. ReisnerRM, Cohen JR. Gallstone ileus: a review of 1001 reported cases. *Am Surg*1994;**60**: 441 – 6.Medline, ISI, Google Scholar
15. Doko M , Zovak M , Kopljar M , Glavan E , Ljubicic N , Hochstädter H . Comparison of surgical treatments of gallstone ileus: preliminary report. *World J Surg*2003;**27**: 400 – 4. Crossref, Medline, ISI, Google Scholar
16. Mallipeddi MK, Pappas TN, Shapiro ML, Scarborough JE. Gallstone ileus: revisiting surgical outcomes